



Prof. Kakarla Subbarao



REVIEW ARTICLE

Musculoskeletal fluorosis – imaging spectrum

Prof. Kakarla Subbarao^{1,*}

¹Chairman, KIMS Foundation and Research Centre, Minister Road, Secunderabad - 500003, AP, India

***Corresponding author:** Prof. Kakarla Subbarao, MS, D.Sc. (HON), FRCR, FACR, FICP, FSASMA, FCCP, FICR, FCGP, Chairman, KIMS Foundation and Research Centre, Minister Road, Secunderabad - 500003, AP, India.

Received 13 August 2013; Accepted 23 September 2013

Citation: Kakarla Subbarao (2013) Musculoskeletal fluorosis – imaging spectrum. *J Med Sci Res* 1(3): 117–123.

Copyright: © 2013 KIMS Foundation and Research Centre. All Rights Reserved.

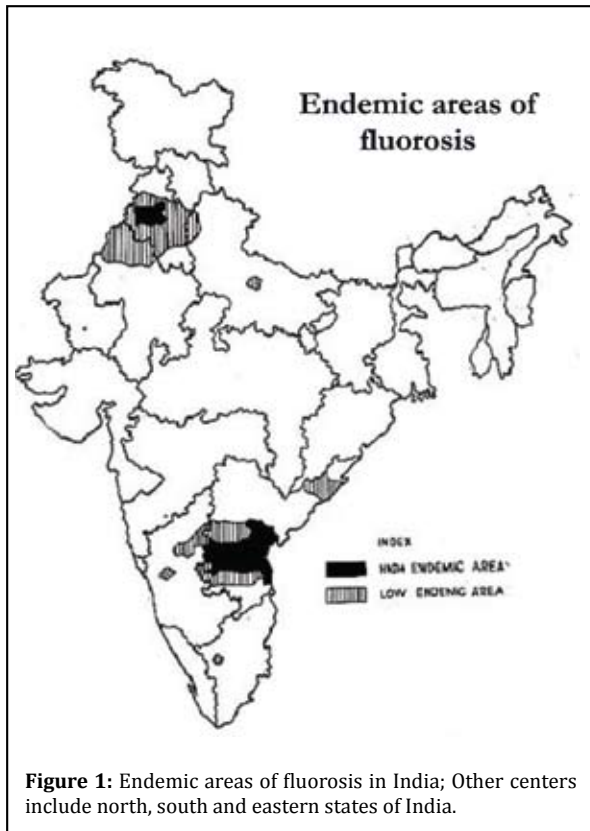
Introduction

Normal mineralization of bones and formation of dental enamel depend upon fluorine partially. Fluorine is amply available in nature. The human body contains 96% fluoride in bones and teeth. The biological half life of fluoride in bone is about 20 yrs. The factors that influence musculoskeletal changes due to excess of fluorides include endemic areas, age, diet, drinking water, dose, duration and hormonal responses. Consumption of drinking water from wells, food from sea fish, vegetables grown in fluoride area and milk from the cattle, influence the extent of fluorosis. This is a public health problem and is preventable. If detected early it is curable.

About 66 million people in India drink water containing elevated levels of fluoride. Inhalation of fluorine in aluminum industrial workers and farmers using fertilizers may also get fluorosis. When a mother is exposed to excess of fluorides, the infant may have respiratory distress. Fluorosis is endemic in 20 states in India. Andhra Pradesh, Gujarat and Rajasthan are the major centres (Figure 1).

Pathophysiology

Continuous intake of 2.5 mg of fluoride for more than six months deposits, four thousand to six thousand mg per kg of fluoride which causes detectable radiological changes in musculoskeletal system. The hydroxyapatite in bone is altered in size and structure of its crystal. The fluoroapatite crystal decreases the mechanical competence of the bone. The poor quality of bone results in fractures and osteoarthritis. Musculoskeletal fluorosis is



aggravated by deficiency in calcium and vitamin 'D' particularly in children.

The histology presents as cement lines, increased osteocytes, disoriented lamellae, altered enzymatic action and poorly formed Haversian system.

Radiological findings

Musculoskeletal fluorosis involves all the bones from head to toe. The paraarticular soft tissue structures that are involved include musculotendinous areas, ligaments, fascia, bursae and other structures.

In the skull, calcifications of petroclinoid ligaments, diaphragma sella, ligamentum nuchae etc., are observed. In the calvarium, diploic thickening prominent occiput and frontal ridges are noted (Figure 2).

In children and women, rickets and osteomalacia are present due to deficiency of calcium and vitamin 'D'. Rachitic changes include widening of the physes and metaphyseal cupping (Figure 3a).

Stress lines may be detected depending upon the health status of the child (Figure 3b).

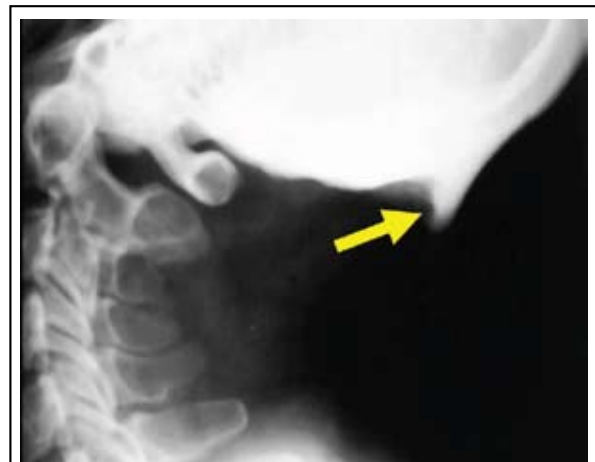

Figure 2: Fluorosis with occipital exostotic ossification; Sutural sclerosis and irregular narrowing of foramen magnum are also present.

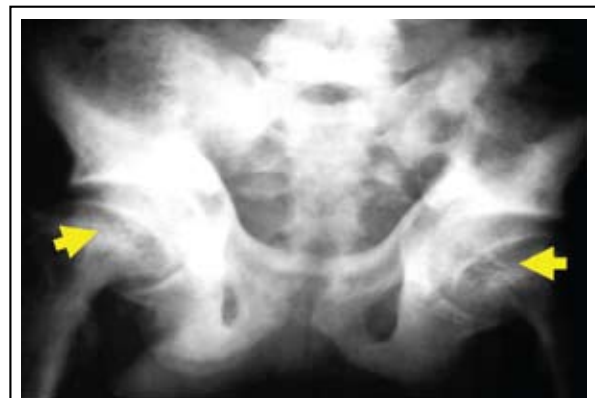

Figure 3a: 12 yr old - Fluorosis with rickets. Note widening of physes

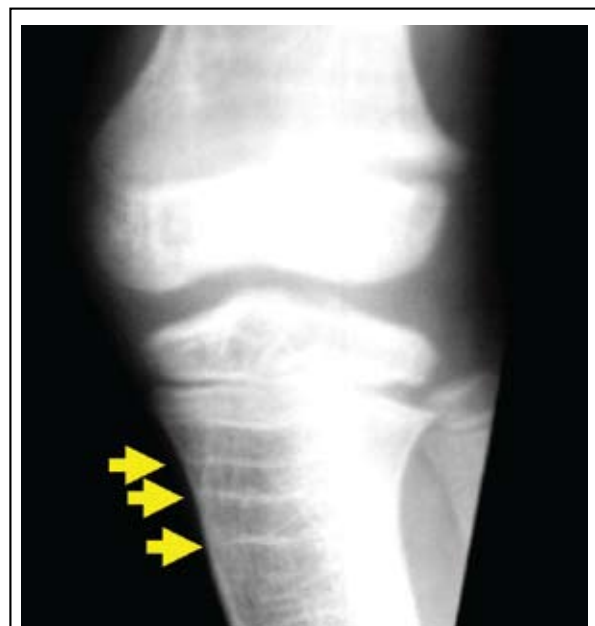

Figure 3b: Rickets + Stress Lines

In adults, osteomalacia is noted as ground glass appearance of bones which are soft with Looser zones (Figure 4).

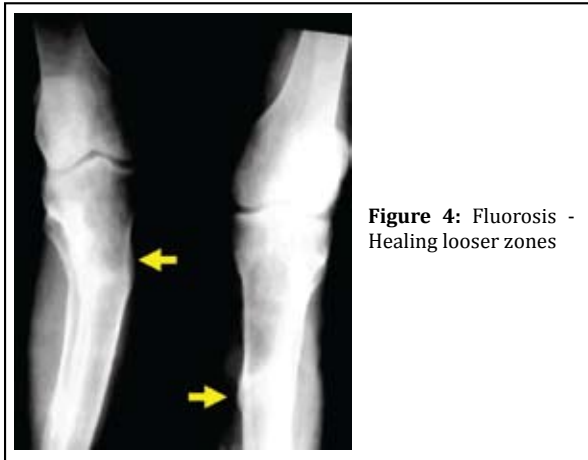


Figure 4: Fluorosis - Healing looser zones

In adults, diffuse sclerosis of the axial skeleton with enthesopathy, calcification of the paravertebral ligaments and ligamentum flava are noted (Figure 5ab).

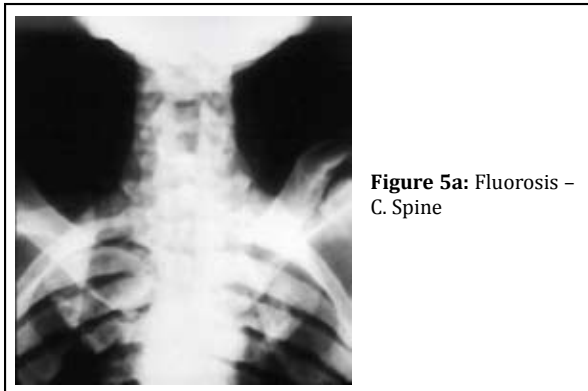


Figure 5a: Fluorosis - C. Spine

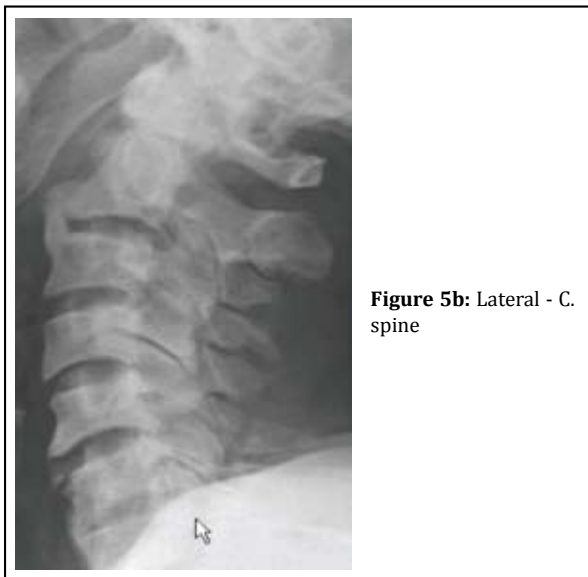

Figure 5b: Lateral - C. spine

In the cervical spine, the anterior longitudinal ligament may have flowing hyperostosis simulating diffuse idiopathic skeletal hyperostosis (DISH) (Figure 5c).

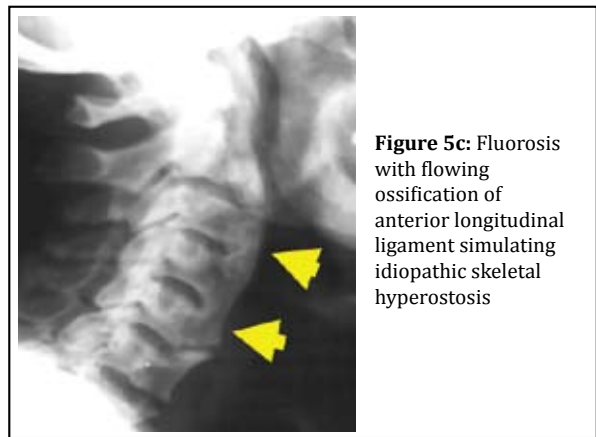


Figure 5c: Fluorosis with flowing ossification of anterior longitudinal ligament simulating idiopathic skeletal hyperostosis

In the thoracic spine diffuse sclerosis with enthesopathy is noted (Figure 6ab).

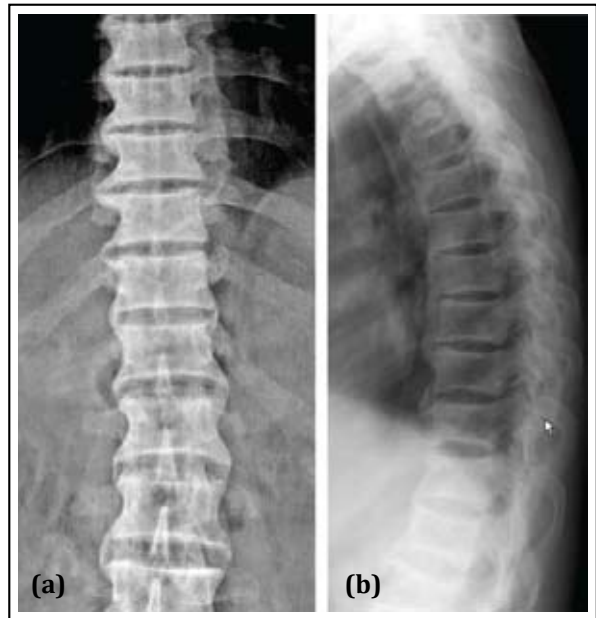


Figure 6ab: Fluorosis - Thoracolumbar spine with sclerosis and enthesopathy

Ossification of ligamentum flava may produce pressure effects on spinal cord. Degenerative changes may be super imposed in spine. Early on, osteoporosis may be noted.

In the thoracic cage, the ribs show diffuse sclerosis with saw tooth like appearance in the superior and inferior borders due to calcification at the attachment of intercostal muscles and interosseous membranes (Figure 7ab).

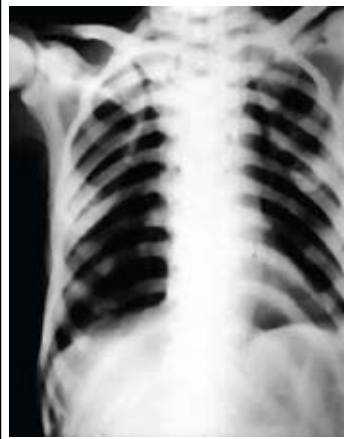


Figure 7a: Fluorosis thoracic cage

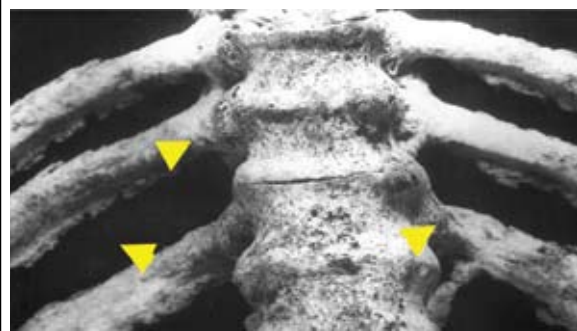


Figure 7b: Fluorosis specimen - Interosseous muscular attachments

In the pelvis, ligamentous calcification is noted in obturator membrane, sacrospinous, sacrotuberous and paraarticular ligaments. Lumbosacral ligament is also ossified. These appearances depend upon the degree of toxicity. Bony excrescencies simulating exostosis are noted in the iliac crest. Ischial tuberosities and bony protuberances. The ischial changes show simulating “whiskerng” noted in ankylosing spondylitis (Figure 8 abcd).

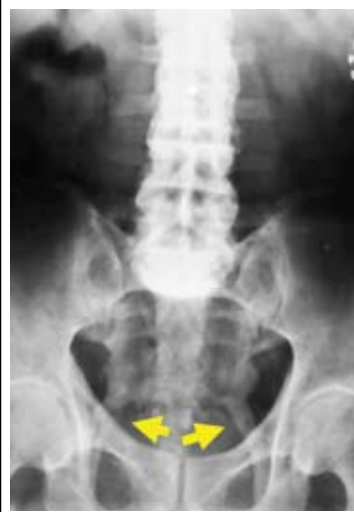

Figure 8a: Fluorosis - Calcified sacrospinous and sacrotuberous ligaments

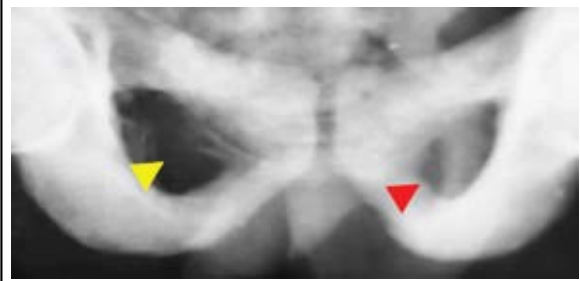


Figure 8b: fluorosis - Calcification of the obturator membrane and ischiosacral ligament

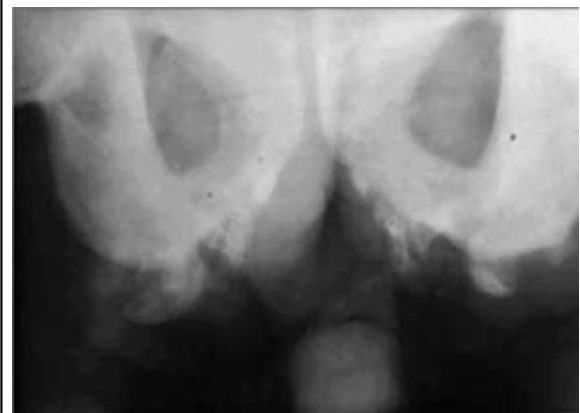


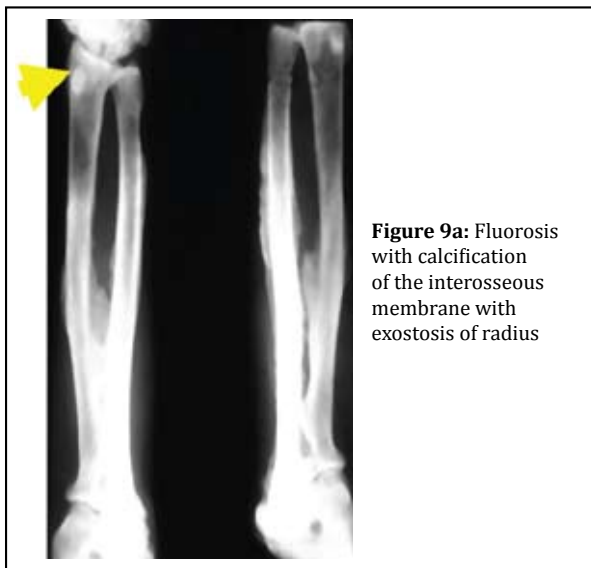
Figure 8c: Fluorosis - Exuberant enthesopathy at ischial tuberosities

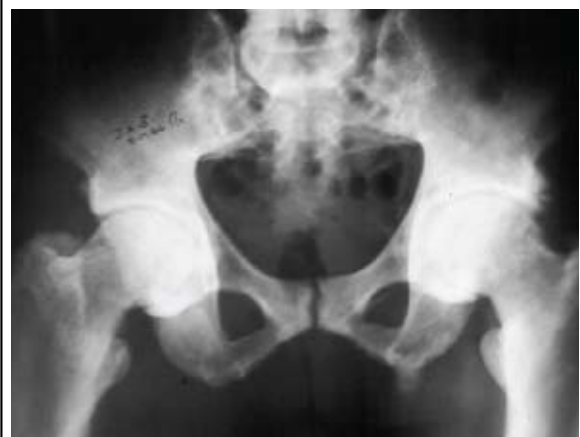

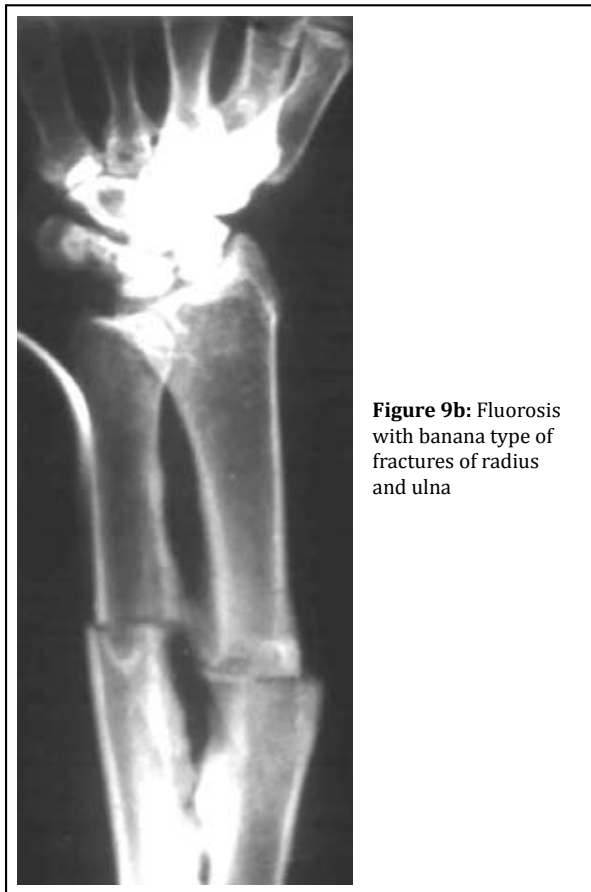Figure 8d: Fluorosis + degenerative changes in hip joints and ischial enthesopathy

The appendicular skeleton shows variable changes depending upon the stage of fluorosis. The primary trabeculae appear to be rough and sclerotic. These thick primary trabeculae merge with secondary trabeculae to make bones homogenously dense. The contours of bone are uneven due to subperiosteal new bone opposition. The long bones of the limbs show encroachment of the medullary cavities with endosteal new bone. Calcification of the interosseous membrane of the forearm is classical

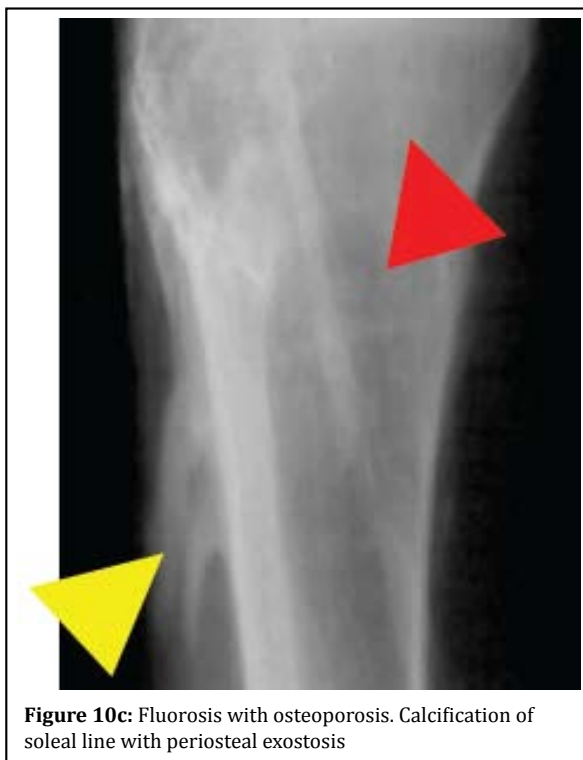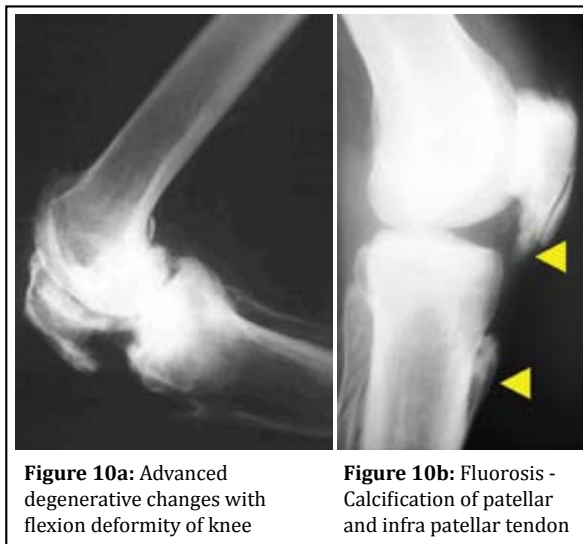
of fluorosis, although it may be occasionally noted in diffuse idiopathic skeletal hyperostosis. Sclerotic changes and periosteal proliferation in the bones of the forearm and hand are common and periosteal proliferation may simulate exostoses (Figure 9a).



Pathological fractures of banana type may noted (Figure 9b).



Often, degenerative changes are noted in the knee joints with calcification of paraarticular structures and tendons resulting in deformities (Figure 10abc).



Spinal and root canal stenosis are well appreciated with concomitant changes in the spinal cord. The facet joints and the calcification of ligamentum flava are well depicted (Figure 14ab).

MRI imaging

Although it is costly, it is non invasive and radiation free. Spinal cord changes as well as the soft tissues

In the bones of the foot and ankle, similar changes are noted with extensive calcification/ ossification at the insertion of tendoachilles at the calcaneum (Figure 11).

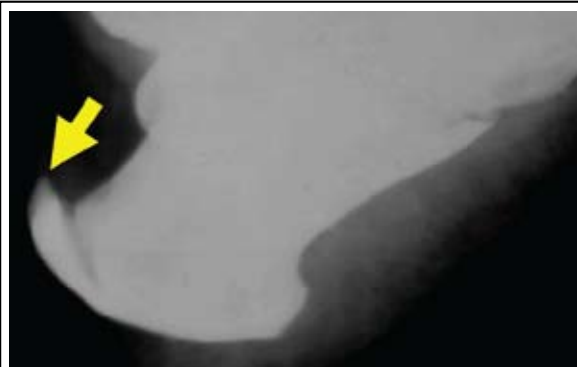

Figure 11: Fluorosis with dorsal calcaneal spur

In the teeth, white patches on enamel, faint yellow lines leading to brown stain and pitting of enamel with clipped of edges are noted.

Ct imaging

CT is the best imaging modality to study the bone pathology (Figure 12).

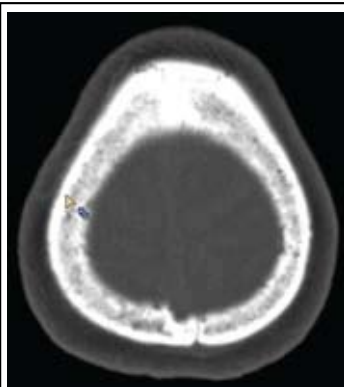


Figure 12: Fluorosis - CT skull showing diffuse sclerosis

It shows enthesopathy and calcification of the ligaments (Figure 13).

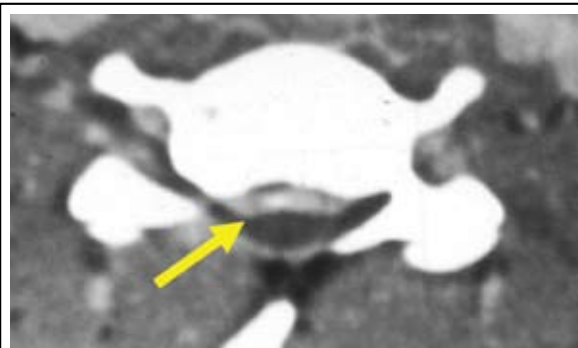


Figure 13: Fluorosis CT - C. Spine - Ossification of posterior longitudinal ligament (arrow) (OPLL)

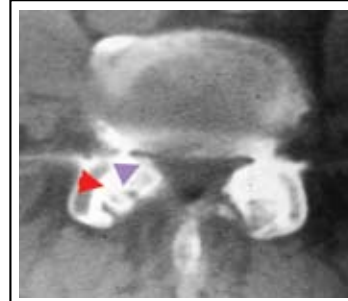


Figure 14a: Fluorosis CT - Lumbar canal stenosis with calcified ligamentum flavum

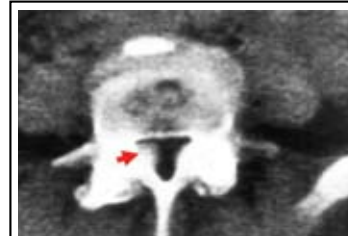

Figure 14b: Fluorosis CT - Lumbar canal stenosis with calcified ligamentum flavum

are well demonstrated. The spinal cord changes are mainly due to prolonged compression and secondary vascular compromise producing myelomalacia. Fluorotic vertebrae are hypointense in both T1 & T2 weighted images. Myelomalacia, cavitation and necrosis show high intensity signal in T2 weighted images (Figure 15abcd).

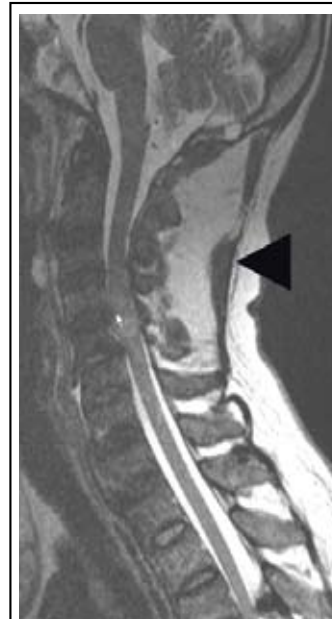

Figure 15a: Fluorosis MRI - C. Spine. Note the ischemic changes in the cord and ossification of ligamentum nuchae (Black arrow)

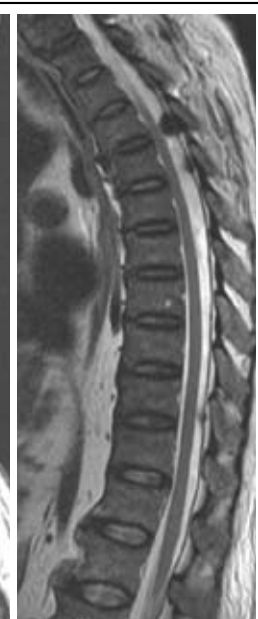

Figure 15b: Fluorosis MRI - Extensive calcification of ligamentum flava

Scintigraphy

Radionuclide bone scans are mostly performed by technetium labeled methylene diphosphonate. It

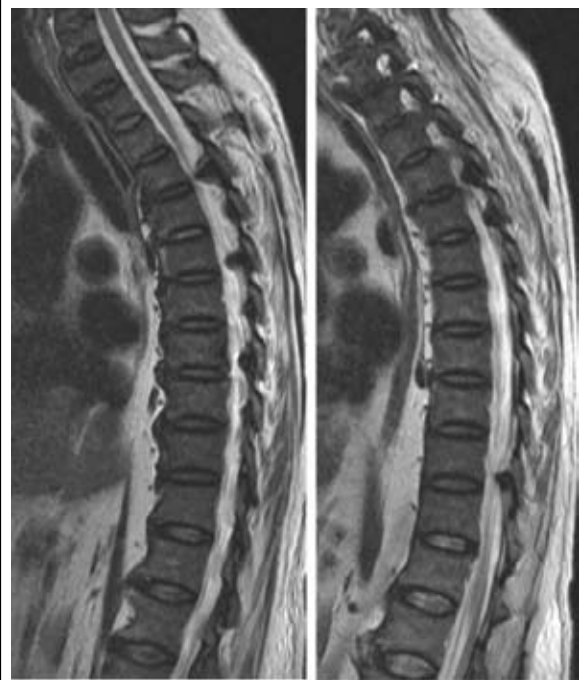


Figure 15cd: Fluorosis MRI – Extensive ossification of ligamentum flava with compression of the cord

mostly shows super scan and in most cases joint abnormalities. The tracer concentration is high in the articular margins. In general, scintigraphy is useful in displaying skeletal fluorosis.

Differential diagnosis

Myelofibrosis, osteoblastic metastasis, renal osteodystrophy, ankylosing spondylitis, Paget's disease etc., are to be considered. Sclerosing dysplasias are diagnosed by skeletal survey.

Complications

The complications include degenerative arthritis, degenerative spondylosis, pathological fractures, neurological abnormalities and secondary hyperparathyroidism.

Conclusion

Fluorosis is a public health problem which is preventable. The radiological changes of musculoskeletal fluorosis depend upon the stage of fluorosis. Conventional radiology is the basic screening method. CT and MRI are helpful to detect changes in the spinal cord. CT detects early calcification better than conventional radiology. MRI helps in the study of changes in the spinal cord. If detected early, the skeletal changes are reversible.

Reference

1. Christie DP. The spectrum of radiological bone changes in children with fluorosis. *Radiology* 1980, 136:85.
2. Dandona P, Menon RK, Shenoy R, Houlder S, Thomas M, et al. Low 1,25-dihydroxyvitamin D, secondary hyperparathyroidism, and normal osteocalcin in elderly subjects. *J Clin Endocrinol Metab* 1976, 63:459.
3. Gruber HE, Baylink DJ. The effects of fluoride on bone. *Clin Orthop Rel Res* 1991, 267:264-277.
4. Jolly SS, Singh BM, Mathur OC. Endemic fluorosis in Punjab (India). *Am J Med* 1969, 47:553.
5. Krishnamachari KAVR. Further observations in syndrome of endemic genu valgum. *Ind J Med Res* 1976, 64:284.
6. Krishnamachari KAVR, Krishnaswamy K. Genu valgum and osteoporosis in an area of endemic fluorosis. *Lancet* 1973, 2:887
7. Naidu MR, Sastry KV, Reddy PK, Reddy DR. Skeletal fluorosis secondary to occult renal disease. *Fluoride* 1986, 19:166-168.
8. Pandit CG, Raghavachari TN, Rao DS, Krishnamurthi V. Endemic fluorosis in south India. *Indian J Med Res* 1940, 28:533-558.
9. Raja Reddy D, Srinikath DR. Fluorosis in Andhra Pradesh – Fluorosis Vimukthi-2012.
10. Raja Reddy D. Neurology of endemic skeletal fluorosis Department of Neurosurgery, Room No. 39, Apollo Hospital, Jubilee Hills, Hyderabad - 500 033, India
11. Rhyan, International fluorosis diagnostic counseling centre, New Delhi, India, Email: fr_rtf@gmail.com.
12. Reddy DR. Some observations of fluoride toxicity. *NIMHANS J* 1985, 3:79-86.
13. Reddy DR, Deme SR, Sesikaran B, Krishnamurthi D, Rao SH, et al. Muscle and nerve pathology in skeletal fluorosis, Reprinted from: 11th International congress of neurological surgery. Amsterdam The Netherlands: July 6-11, 1997, p.2125-2132.
14. Reddy SG, Rao NBS. Effect of dietary calcium, vitamin C and protein in development of experimental skeletal fluorosis. II. Calcium turnover with ⁴⁵Ca; calcium and phosphorus balances. *Metabolism* 1971, 20:650
15. Reddy DR, Skeletal fluorosis. In: Vinken PJ, Bruyn GW, editors. *Handbook of clinical neurology*. Vol. 36. Amsterdam: North Holland Publishing Co; 1979. p. 465-504.
16. Sesikaran B, Harinarayanan Rao S, Krishnamurthi D, Reddy DR. Studies on skeletal muscle biopsies in endemic skeletal fluorosis. *Neurol India* 2000, 48:187-198.
17. Shortt HE, McRobert GR, Barnard TW, Nayar AS. Endemic fluorosis in the Madras presidency. *Indian J Med Res* 1937, 25:553-568.
18. Siddique AH. Fluorosis in Nalgonda district, Hyderabad, Deccan. *Br Med J* 1955, 2:1408.
19. Teotia SPS, Teotia M. Secondary hyperparathyroidism in endemic fluorosis. *Br Med J* 1973, 1:637
20. Teotia M, Teotia SPS, Kunwar KB, et al. Endemic skeletal fluorosis, *Arch Dis Child* 1971, 46:686-691. doi:10.1136/ad.46.249.686.
21. World Health Organization. *Environmental Health Criteria* 227, Fluorides, Geneva: W.H.O. 2002. p.14-16.